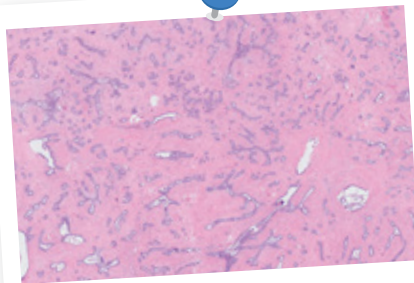




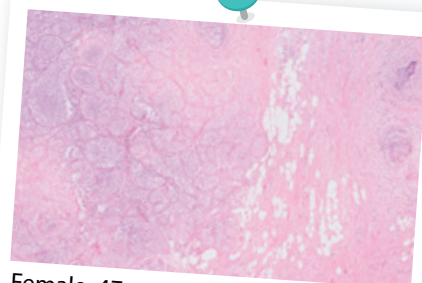
A Daydreaming Surgeon

Text and photos by Dr Tan Yia Swam and Dr Jipson Quah

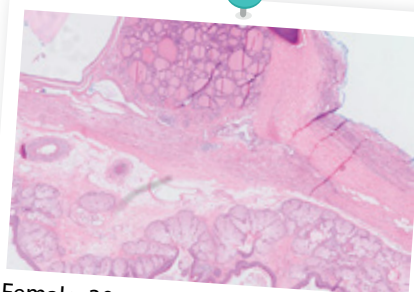
At tumour board reviews, one of the residents will present the patient's clinical history, a radiologist will highlight the relevant imaging, and the pathologist will then point out critical points in the biopsy or surgical specimen that will affect subsequent management (eg, equivocal diagnosis of invasive vs pre-invasive cancers, margins). This is relevant to recommendations for additional surgery, or need for chemotherapy. It helps when my dear pathologists at KK Women's and Children's Hospital, namely Dr Gudi Mihir, Dr Lim-Tan, Dr Chew Sung Hock and Dr Leong May Ying, zoom in on where exactly the cancer cells are. Otherwise, what goes through my mind when I look at the big picture would be similar to what you are about to read on the next page. Dr Jipson Quah has collated some classical images of common diagnoses, and I have allowed my creative mind to wander and daydream a bit. What do YOU see?



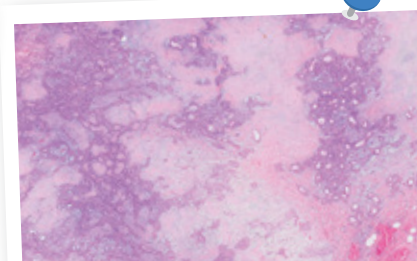
Female, 25 years old
Chest lump



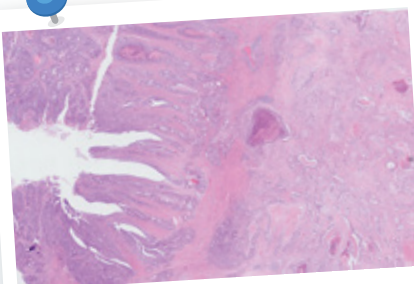
Female, 47 years old
Breast lump



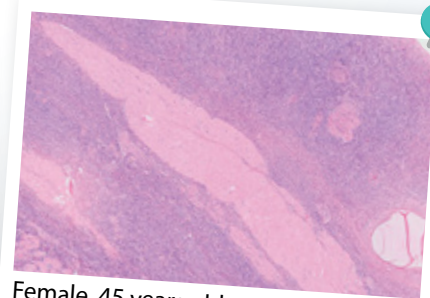
Female, 30 years old
Abdominal mass



Female, 33 years old
Cheek swelling



Male, 62 years old
Rectal bleeding

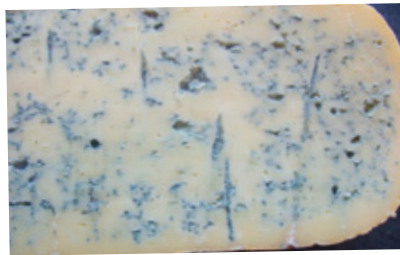


Female, 45 years old
Total hysterectomy with bilateral
salpingo-oophorectomy

Dr Tan Yia Swam is a consultant at the Breast Department of KK Women's and Children's Hospital. She continues to juggle the commitments of being a doctor, a mother, a wife and the increased duties of SMA News Editor. She also tries to keep time aside for herself and friends, both old and new.



Dr Jipson Quah is currently a resident in the Department of Histopathology at Singapore General Hospital. He enjoys music-making, fitness-related activities and editorial work in his free time.



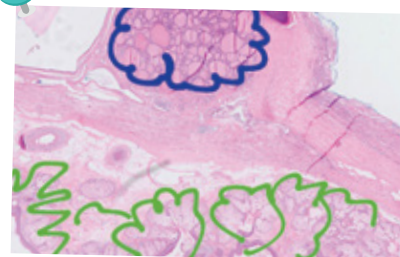
*"Is this some kind of cheese?
Like Bleu d'Auvergne? Bleu de Gex?"*

Diagnosis: Fibroadenoma, defined by the proliferation of breast epithelial and stromal components



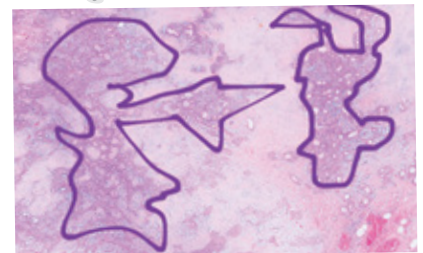"Reflections of the cherry blossom trees in a river..."

Diagnosis: Breast lobular carcinoma in situ, seen from the presence of uniform malignant cells packed into lobules



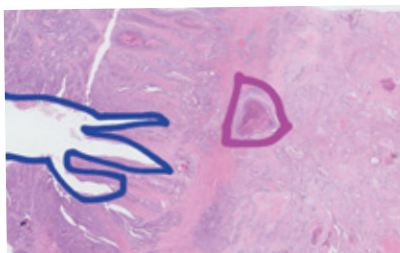"I see lagoons at the top and coral reefs at the bottom... So where's Nemo?"

Diagnosis: Mature teratoma, evident from the presence of thyroid tissue, hair follicles, bone and cyst wall lining



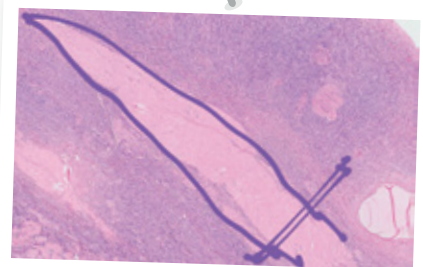
"Erm... I see a boy shooting at a deformed rabbit."

Diagnosis: Pleomorphic adenoma, proliferation of epithelial and myoepithelial cells in a myxoid stroma



"This looks like a monster hand reaching out to grab a crystal."

Diagnosis: Colorectal adenocarcinoma, with invasion into muscularis propria



"The Spear of Destiny!"

Diagnosis: Normal ovarian histology, comprising of corpus albicans and ovarian stroma ♦